

Long-term deprivation affects visual perception and cortex

Ione Fine¹, Alex R Wade², Alyssa A Brewer³, Michael G May⁵, Daniel F Goodman⁶, Geoffrey M Boynton⁷, Brian A Wandell^{3,4} & Donald I A MacLeod¹

Recovery after long-term blindness was first studied¹ in 1793, but few cases have been reported since^{2–7}. We combined psychophysical and neuroimaging techniques to characterize the effects of long-term visual deprivation on human cortex.

At three and a half years old, our subject MM lost one eye and was blinded in the other after chemical and thermal damage to his cornea. Limbal epithelium damage prevented successful replacement of MM's cornea for 40 years; he had some light perception, but no experience of contrast or form. One unsuccessful corneal replacement was attempted in childhood, but he reported no visual memories or imagery. At age 43, MM received a corneal and limbal stem-cell transplant in his right eye.

After surgery, MM's spatial contrast sensitivity function (CSF) was close to that of control observers for low spatial frequencies (Fig. 1a). However, the highest spatial frequency visible at full contrast was 1.3 c.p.d., compared to 30–40 c.p.d. in controls, and had not improved two years after surgery⁸. MM's optical quality was 20/40 or better, much higher than his resolution limit. His retina was visible through an ophthalmoscope, with no indications of degeneration, and electroretinogram responses were normal, suggesting that his insensitivity is of central origin. Functional magnetic resonance imaging (fMRI) BOLD responses to low-frequency gratings were about half those of controls in motion-selective cortex (MT+) and about one-fifth those of controls in the area we defined as V1 (see Supplementary Note and Supplementary Fig. 1 online). Unlike controls, these fMRI responses (as well as visual evoked potentials) fell off rapidly with increasing spatial frequency, with little or no response above 1 c.p.d. (Fig. 1b). At age 3, MM's acuity should have been at least 25 c.p.d.⁹, suggesting that prolonged deprivation had degraded the spatial resolution of his early visual cortex.

MM had no deficits in simple form tasks (Fig. 2). When first tested, five months after surgery, he perceived slight changes in the orientation of a bar and easily recognized simple shapes (Fig. 2a). He reported perceiving simple shapes even immediately after surgery. Like most^{2,3}, though not all⁵, earlier sight-recovery patients, he identified colors easily, and his equiluminance settings (measured by flicker minimization) were normal.

The effects of deprivation on processing in cortical areas beyond V1 have rarely been measured^{10,11}. MM could segment texture patterns based on luminance contrast (Fig. 2b), but was slightly worse than controls at form tasks requiring integration of texture elements, such

as identifying whether a field of line contours contained a sequence of nearly collinear segments (Fig. 2c) and distinguishing Glass patterns from random noise (Fig. 2d)¹⁰. MM also had difficulty with 'subjective contours'; though he recognized outlined 2D shapes, he could not identify them in Kanisza figures (Fig. 2a,e).

Like other sight-recovery patients, MM has difficulty with 3D interpretation of retinal images. He could use occlusion cues, seeing two L-shapes (Fig. 2f) in the depth relations suggested by their T-junctions. MM could also interpret shading cues (Fig. 2g), though this seemed to be based on explicit reasoning that illumination is usually above objects. Transparency was problematic: he described two overlapping transparent squares (Fig. 2h) as three surfaces with the central square in front—consistent with his perception of occlusion. MM was also insensitive to perspective cues; like SB (ref. 2), he could not identify wire drawings of Necker cubes (Fig. 2i) in any 3D orientation, describing the cube as "a square with lines". MM was also immune to perspective cue illusions, correctly choosing the quadrilaterals in Fig. 2j as rotated versions of each other. Controls (mistakenly) choose a stretched version of table (ii), even when asked to match the projected 2D image shapes.

These form deficits extended to object and face recognition. MM identified only 25% of common objects, and he had difficulty judging gender (male/female, 70%) or expression (happy/neutral/sad, 61%) in unfamiliar faces. He reported relying on individual features, such as hair length or eyebrow shape¹². Faces and objects evoked little fMRI activation within MM's lingual and fusiform gyri, where controls had strong responses (Fig. 3). In MM, these stimuli activated occipital regions near calcarine cortex. He saw the images, but, like other sight-recovery cases^{2,3}, had difficulty interpreting them, and face- and object-processing areas of cortex were inactive.

MM was successful at many motion tasks. He easily identified the direction of simple and complex plaid motion and perceived the barber pole illusion (Fig. 2k). He segregated textured fields based on motion (Fig. 2l) and could distinguish rotational Glass motion patterns (two successive frames differing by rotation) from random noise (Fig. 2m). MM could use motion cues to compute 3D shape: a stationary Necker cube was uninterpretable, but he immediately saw a cube when motion-in-depth was simulated (Fig. 2n). MM (like Virgil³) was sensitive to

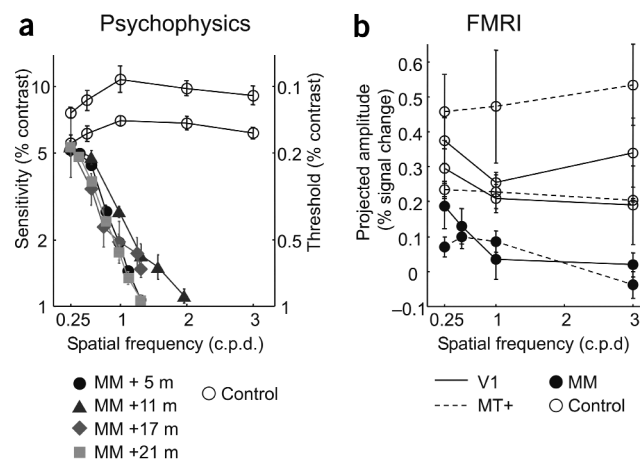
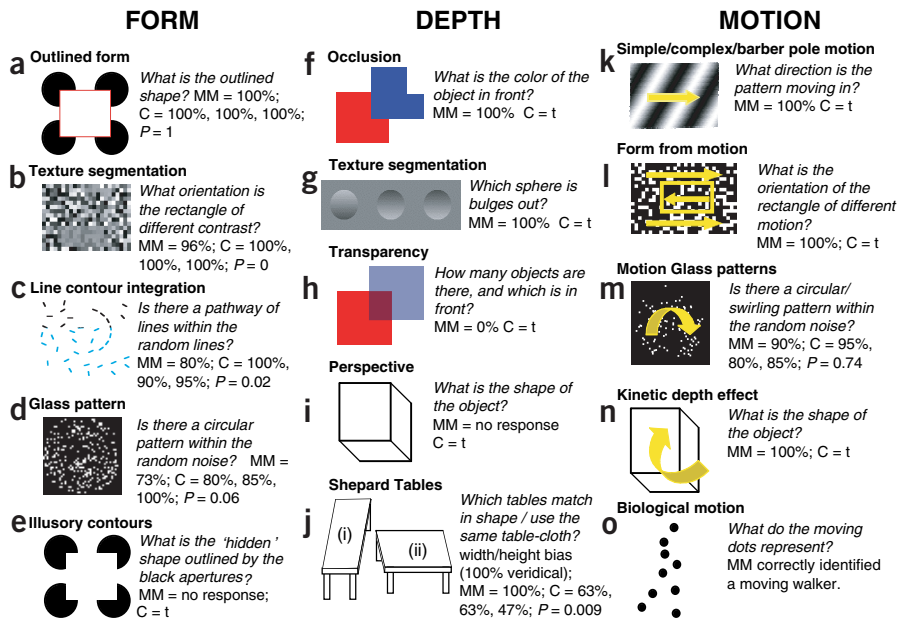


Figure 1 (a) MM's sensitivity as a function of spatial frequency measured psychophysically using a method of adjustment 5–21 months after surgery. (b) Neural responses as a function of spatial frequency measured using fMRI in MT (dashed line) and V1 (solid line). Error bars are based on averaging over independent scans. All subjects gave written informed consent. These experiments were approved by the UCSD Human Research Protections Program.

¹Department of Psychology, University of California, San Diego, 9500 Gilman Drive, La Jolla, California 92093, USA. ²Smith Kettlewell Eye Research Institute, 2318 Fillmore Street, San Francisco, California 94115, USA. Stanford University Departments of ³Neuroscience and ⁴Psychology, Stanford, California 94305, USA. ⁵Sendero Group, LLC, 175 Mason Circle, Concord, California 94520, USA. ⁶California Pacific Medical Center, 1199 Bush Street, Suite 350, San Francisco, California 94109, USA. ⁷The Salk Institute, 10010 North Torrey Pines Road, La Jolla, California, 93037, USA. Correspondence should be addressed to I.F. (fine@salk.edu)

Figure 2 Stimuli, tasks and performance for tests of MM's form, depth and motion processing. Stimuli shown to controls (C) were always blurred using a low-pass filter (cutoff 1 c.p.d.) to match MM's spatial resolution losses. Some tasks were trivial for controls (t) and were not formally tested. *P*-values, one-tailed *t*-tests, MM worse than controls.



biological motion, recognizing a human walking ('Johansson') figure portrayed only by point sources at critical joints (Fig. 2o). MM's ability to interpret 3D form from motion suggests that performance may have been mediated by MT/MST¹³. His fMRI responses in MT had normal strength and area (left MT+, 9.23 cm²; controls, 7.06, 9.14, 7.78 cm²; right MT+, 7.6 cm² for MM; controls, 6.46, 6.47, 9.61 cm²; *P* = 0.28, one-tailed *t*-test, both hemispheres). MM's spared 3D motion processing was noticeable in daily life. Within a year of his operation, MM reported he could catch a large brightly colored ball 80% of the time.

Monocular deprivation beyond 30 months of age causes severe amblyopia with little or no recovery of visual function¹⁴, but visual experience beyond age three also seems to be necessary for normal visual processing. Most effects of MM's deprivation seem to be long-lasting. Neither neural resolution nor form processing has improved two years after the operation, though MM has improved in interpreting motion and shading cues. For example, MM was an expert skier as a blind person (using verbal directions from a guide). Immediately after his operation, he closed his eyes when skiing, as the visual information gave him a frightening sense of imminent collision. Similarly, SB crossed roads confidently when blind, but became nervous doing so once sighted². Over two years, MM has begun to use shading patterns on snow to estimate the shape of the slope. This computation has gradually become more fluent, if not automatic, and he now opens his eyes on all but the most difficult descents. MM now makes significant use of vision in everyday life: "The difference between today and

over 2 years ago is that I can better guess at what I am seeing. What is the same is that I am still guessing."

After compensation for reduced acuity, MM's simple form, color and motion processing were essentially normal. In contrast, complex (especially 3D) form, object and face recognition were severely impaired. Why might motion processing be so robust to deprivation? Studies of subcortical projections to MT/MST suggest that they alone could not support MM's post-operative vision¹⁵. Motion processing develops early in infancy compared to form processing¹⁰ and might therefore have been more established, and consequently robust to deprivation, by the age of three. Alternatively, complex form processing may remain plastic after early development, and thus susceptible to deprivation, because novel objects and faces are encountered throughout life.

Note: Supplementary information is available on the Nature Neuroscience website.

ACKNOWLEDGMENTS

Thanks to V. Iragui for performing VEP and ERG studies, and to S.A. Anstis, E. Holland and H.S. Smallman for help and advice.

COMPETING INTERESTS STATEMENT

The authors declare that they have no competing financial interests.

Received 22 April; accepted 25 June 2003

Published online at <http://www.nature.com/natureneuroscience/>

- Cheselden, W. *Phil. Trans. Lond.* **402**, 447–450 (1728).
- Gregory, R.L. & Wallace, J.G. *Exp. Psychological Soc. Monograph 2* (Heffer and Sons, Cambridge, 1963).
- Sacks, O. in *An Anthropologist on Mars* 108–152 (Vintage Books, Random House, New York, 1995).
- Valvo, A. in *Sight Restoration After Long-term Blindness: the Problems and Behavior Patterns of Visual Rehabilitation* (American Foundation for the Blind, New York, 1971).
- Ackroyd, C., Humphrey, N.K. & Warrington, E.K. *Q. J. Exp. Psychol.* **26**, 114–124 (1974).
- Carlson, S., Hyvarinen, L. & Raninen, A. *Br. J. Ophthalmol.* **70**, 607–611 (1986).
- Morgan, M.J. *Molyneux's Question: Vision, Touch and the Philosophy of Perception* (Cambridge Univ. Press, New York, 1977).
- Carlson, S. & Hyvarinen, L. *Acta Ophthalmol. (Copenh.)* **61**, 701–713 (1983).
- Mayer, D.L. & Dobson, V. *Vision Res.* **22**, 1141–1151 (1982).
- Lewis, T.L. *et al. Vision Res.* **42**, 939–948 (2002).
- Pasternak, T., Movshon, J.A. & Merigan, W.H. *Nature* **292**, 834–836 (1981).
- Le Grand, R., Mondloch, C.J., Maurer, D. & Brent, H.P. *Nature* **410**, 890 (2001).
- Bradley, D.C., Chang, G.C. & Andersen, R.A. *Nature* **392**, 714–717 (1998).
- Vaegan & Taylor, D. *Trans. Ophthalmol. Soc. UK* **99**, 432–439 (1979).
- Collins, C.E., Lyon, D.C. & Kaas, J.H. *J. Neurosci.* **23**, 2251–2264 (2003).

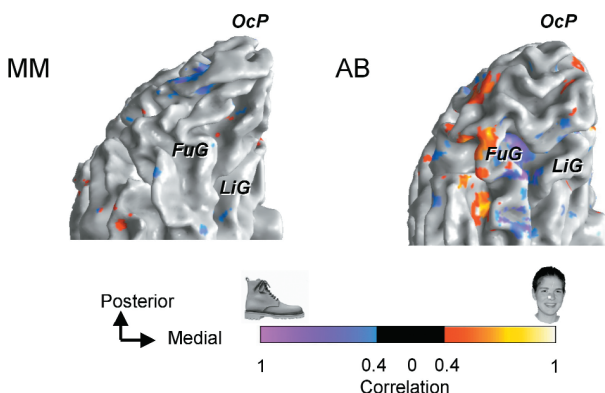


Figure 3 Left hemisphere activation in response to faces versus objects, regions responding at a coherence value above 0.4. Color-coding represents the phase preference of each voxel. We used a block design comparing images of faces versus scrambled faces, objects versus scrambled objects, faces versus objects (shown) and faces versus blank. Red-orange, regions that responded more to faces. Green-blue, regions that responded more to objects. Control AB showed a typical pattern of activation, with large contiguous regions that responded more either to faces or objects near the fusiform gyrus (FuG) and lingual gyrus (LiG). In contrast, MM showed little activity to objects, and almost no activity to faces.